

MANAGEMENT OF ACNE SCARS WITH PLATELET-RICH-PLASMA (PRP) THERAPY AS A TVAKA RASAYANAM

Dr. Anupama Thakur^{1*} and Dr. Rajesh Sood²

¹M.D. Scholar in Samihta & Siddhanta,

²Reader and in Charge of Skin Care Unit,

Rajiv Gandhi Govt. Postgraduate Ayurvedic College, Paprola (H.P.).

Article Received on
22 July 2018,

Revised on 12 August 2018,
Accepted on 01 Sep. 2018

DOI: 10.20959/wjpr201816-13317

*Corresponding Author

Dr. Anupama Thakur

M.D. Scholar in Samihta &
Siddhanta, Rajiv Gandhi
Govt. Postgraduate
Ayurvedic College, Paprola
(H.P.).

ABSTRACT

Introduction: Acne vulgaris can lead to lifelong sequel in the form of atrophic or hypertrophic scars, depending on the degree of inflammation. Acne scar management remains a challenge to dermatologists. Platelet rich plasma (PRP), in which the platelets are in a highly concentrated form, has shown its effect in accelerating tissue repair and wound healing. The platelet releases a variety of growth factors which bring about tissue remodelling. **Aim:** To study the efficacy and safety of PRP in managing acne vulgaris as *tvak rasayanam* at Skin Care Unit, R.G.G.P.G. Ayurvedic College, Paprola, Kangra(H.P.). **Materials and Methods:** Based on inclusion and exclusion criteria twenty patients were included in the study. PRP was

made by double spin method. The area to be treated was cleaned with spirit and betadine, the skin was stretched and activated PRP loaded in an insulin syringe was injected into and around the scars by multiple punctures. **Results:** out of 20 patients, 20% patients (4) showed marked improvement in the grading of acne scars, i.e. they improved upto grade 1 or there was an improvement by 2 grades. 50% patients (10) showed moderate improvement. In these patients grading of acne scars improved by 1. In 15% patients (3) although the grading did not changed but there was visible improvement in the appearance of the scars. In only 15% patients (3), there was no significant improvement was seen even after 4 sittings but texture of skin is mildly improved. **Conclusion:** Platelet- Rich-Plasma(PRP) therapy is easy to perform. Done as an out patient procedure. it doesn't hamper the daily activities quality of the patient. It works well for superficial acne scars, providing good results with minimal side

effects like erythema and edema which subside within 2-4 hrs. PRP is thus an effective modality for treating acne scars.

KEYWORDS: Acne scars, *Tvaka Rasayanam*, Platelet- Rich-Plasma(PRP).

INTRODUCTION

Acne is a disease of pilosebaceous unit commonly affecting adolescents. Clinically characterized by pleomorphic eruptions, in most cases it is self limiting. However, it is often associated with scarring, varying from minimal to severe^[1], depending on the degree of inflammation occurring during the disease process.^[2] The scars, either atrophic or hypertrophic, occur due to defective tissue healing. Management usually involves a combination of treatment modalities as a single approach may not produce desired results.

Ayurveda has been given the prime importance for managing cosmetic issues amongst all the sectors. As we responsible Ayurvedic Physicians, we must also put in our best efforts for studying and exploring remedies and imbibe the new treatment modalities as an integrative approach.

Ayurvedic physiology is based on *Tridosha* (biological entities responsible for body functioning and its regulation), *Dhatu* (tissues), *Mala* (waste products), *Agni*(biofire), *Shrotas* (body channels).^[3] Rakta dhatu has been considered as *Pranayatana* (seat of life)^[4] because the blood plays an vital role in sustaining of life and for the same reason, its function is also said as *jeevanam*(sustaining life). The nutritional status of all the tissues depend on the status of *Ras-Rakta Dhatu*.^[5]

Platelet- Rich-Plasma(PRP) has been researched and used in various fields of medicine and has emerged as a novel treatment modality. There is evidence to suggest that it is effective in the treatment of atrophied acne scars. It has been found that Platelet- Rich-Plasma(PRP) can be injected into the scars to revert the skin miniaturization.

Platelet- Rich-Plasma(PRP), a new biotechnology, is the product of a heightened interest in cell-based therapy and tissue engineering.^[6] This therapy is defined as an autologous preparation of plasma with concentrated platelets are re-injected into the area where their effect is required. PRP contains various growth factors and cytokines that enhance the body's inherent capacity to repair and regenerate. It is effective in accelerating tissue repair and wound healing.^[7] PRP has been traditionally employed in periodontal therapy, maxillofacial

surgery, orthopaedics and sport medicines.^[8] More, recently it has captured attention in the field of dermatology, particularly for its role in treating acne scars, fat grafting, wound healing and hair regrowth. Research has demonstrated the beneficial effects of PRP, such as proliferation of adipose precursor cells, wound repair, cellular differentiation and angiogenesis.

AIMS AND OBJECTIVES

1. The patients were selected for the study, treated with autologous PRP for 3 months. To evaluate the safety and clinical efficacy of Autologous PRP injections for acne scars.
2. A review of the literally concept related to the use of PRP in Ayurveda.
3. Proposal of Guidelines for future treatment evaluation by adopting Ayurveda principles as an integrative approach.

MATERIALS AND METHODS

Review of research papers and articles was searched online from scientific electronic databases as PubMed, Google scholar, MEDLINE, Clinicaltrials.gov etc. were analysed.

Study Design: It was an open monocentric and prospective study was conducted at Skin Care Unit, R.G.G.P.G. Ayurvedic College, Paprola, Kangra(H.P.) on 20 patients aged from 20 to 30 years old with post acne scars over face. All patients provided written consent before participating in the study.

Inclusion criteria – Acne patients of both sexes, aged above 18 years with atrophic acne scars and those willing for follow up and being photographed.

Exclusion criteria –it includes active nodulocystic acne, active skin infections, keloidal tendency, bleeding disorders, oral steroids, pregnancy and diseases like SLE, porphyria and patients on oral isotretinoin for past one month.

Table No 1.

Score	Patient's satisfied	Improvement in acne	Improvement in Acne Scars Grade
0	Not at all satisfied	0-25%	Minimal
1	Not satisfied	25 -50%	Mild
2	Partially satisfied	50 -75%	Moderate
3	Satisfied	>75%	Near total
4	Highly satisfied		

PRP Extraction Steps

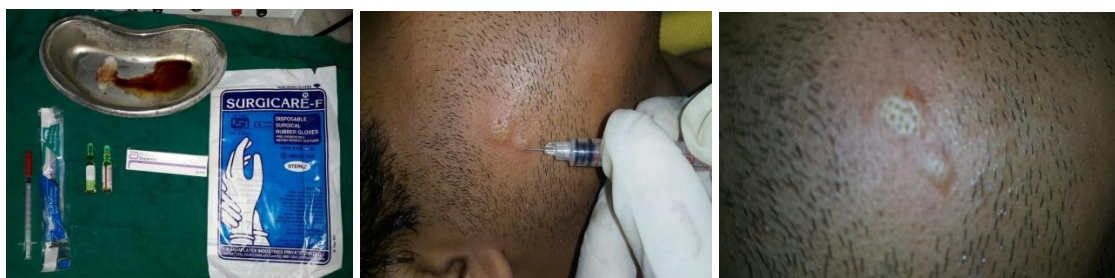1. Obtain whole blood by performing venepuncture using vacutainer tubes with an anticoagulant Acid Citrate Dextrose (ACD) in the ratio of 10: 1.5.
2. Centrifuge the tube in Manual Double Spin method 1500 rpm speed for 6 min. the sample should separate into a yellow top layer (plasma), a thin middle layer – the buffy coat (platelets and wbc's) and a red bottom layer(RBC's).
3. For the production of pure PRP, the upper layer and superficial buffy coat should be transferred to an empty sterile tube.
4. Spin a second time at Manual Double Spin method 2500 rpm speed for 15 min.
5. Remove the upper 3/4th of fluid from the tube.
6. Homogenize the pellet in the remaining 1/3rd of fluid. This is ready to use PRP.
7. 10 % Calcium chloride (1:9) ratio, an activator is added to the platelet- enriched product.

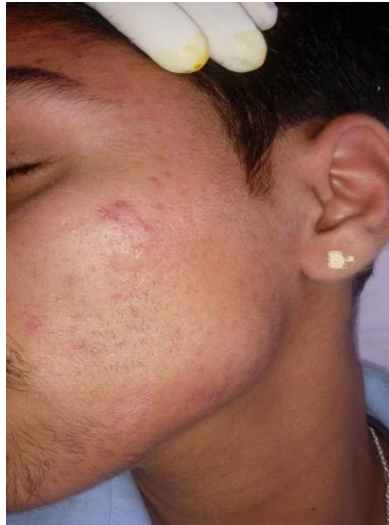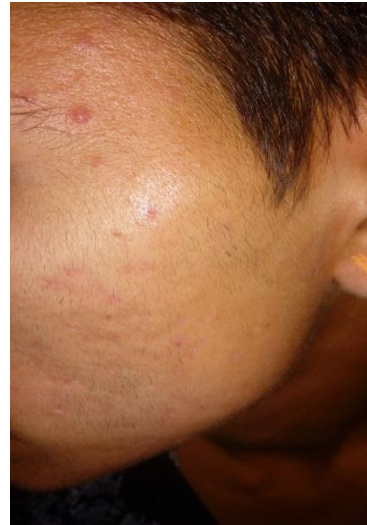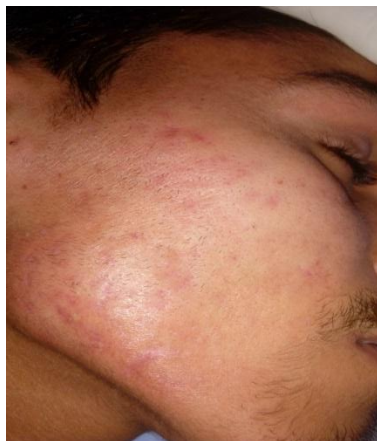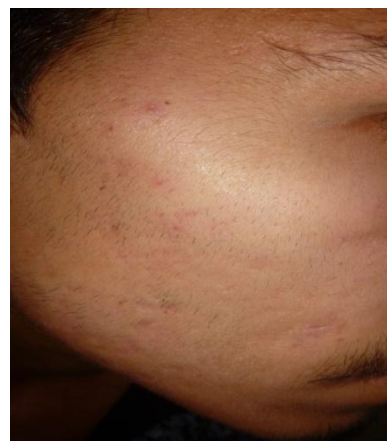Procedure

The area to be treated was anaesthetized with topical anaesthesia. After about 45 minutes, the area to be treated was cleaned with spirit. The skin was stretched and the activated PRP was loaded in insulin syringe and injected intradermal into the scars and around it through multiple punctures. Mild erythema was seen immediately after the procedure. The face wiped with a mild cleanser.

Post procedure advice and follow up

Patients were advised not to vigorously rub the face for 12 hours and not to take aspirin or other anti-inflammatory drugs while on therapy. No dressing was required. Each patient received 3 series of injections (5-7 ml per session) of PRP at M0, M1, M2 and M3 (every month) and the assessment was done.



PATIENT NO. 1**BEFORE TREATMENT****AFTER 4 SITTING****PATIENT NO. 2****BEFORE TREATMENT****AFTER 6 SITTING****ASSESSMENT CRITERIA****1. Quantitative Assessment****Grading of acne scars**

Macular: Erythematous, hyper or hypopigmented flat topped marks.

Mild: Mild atrophic scars that may not be obvious at social distance of ≤ 50 cm and may be covered adequately by makeup or the normal shadow of shaved beard hair in men.

Moderate: Moderate atrophic scarring that is evident at social distance of >50 cm and may not be covered easily by makeup or the normal shadow of shaved beard hair in men and is not able to be flattened by manual stretching of the skin.

Severe: Severe atrophic scarring that is evident at social distance of > 50 cm and is not covered easily by makeup or the normal shadow of shaved beard hair in men and is not able to be flattened by manual stretching of the skin.

2. Cosmetic Assessment: it was done for comparing standardized digital photographs taken before and after the treatment.

3. Self – Assessment: Questionnaire based on 5 points criteria was filled by each patient. The criteria such as.

- a) change in skin texture(quality).
- b) extent of eruptions over face.
- c) pigmentation of face.

4. Post therapy Assessment: also another questionnaire regarding the quality of life before and after treatment was filled by patients.

OBSERVATIONS AND RESULTS

This study included 20 patients, 12 females and 8 males. the youngest age was 20 years and the oldest was 30 years. Fourteen were in 20-25 and six were in 26-30 yrs age group.

After PRP therapy, out of 20 patients, 20% patients showed marked improvement in the grading of acne scars, that is, they improved upto grade 1 or there was an improvement by 2 grades. 50% patients showed moderate improvement. In these patients grading of acne scars improved by 1. In 15% patients although the grading did not changed but there was visible improvement in the appearance of the scars. In only 15% patients, there was no significant improvement was even seen after 4 sittings but texture of skin is mildly improved.

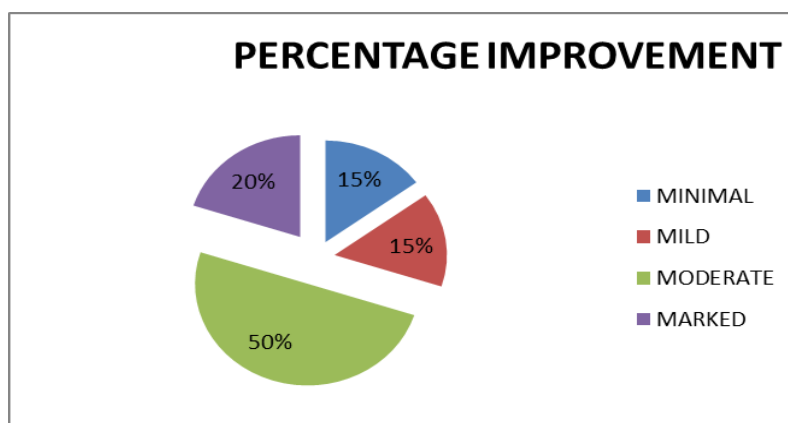


Fig 1: Percentage improvement in Acne Scars.

After 4 sittings of the procedure, appreciable changes were seen on the skin surface of the patients. Marked improvement was seen in 4, moderate improvement in 10, mild improvement in 3 and, minimal improvement in 3 patients. This was seen both objectively and subjectively. (Table : 2).

Table 2: Improvement in acne scars.

Improvement in acne scars	No. of patients
0-25%	3
25-50%	3
50-75%	10
>75 %	4

14 patients were satisfied, 3 patients were partially satisfied and 3 patients were not satisfied.

Table 3: Patient's Satisfaction Score.

Patient's Satisfaction Score	No. of Patients
Not at all satisfied	0
Not satisfied	3
Partially satisfied	3
Satisfied	14
Highly satisfied	0

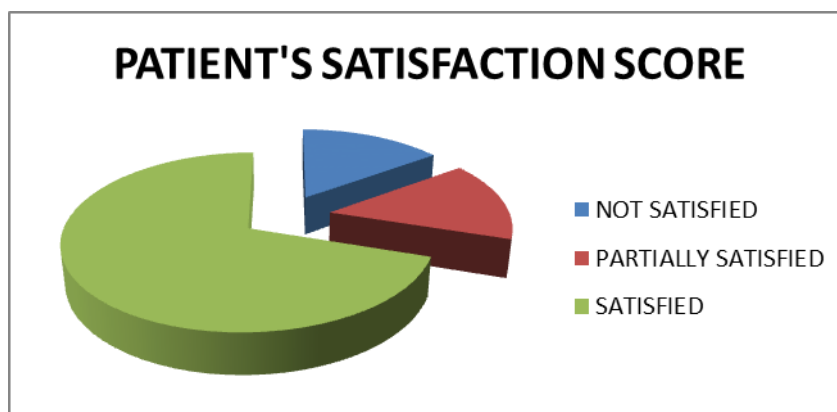


Fig. 2: Patient's Satisfaction Score.

Complications: The major complication was immediate post procedure erythema over face, seen in all 20 patients. The erythema however was transient and resolved in 6-12 hours. Second, even after proper application of numbing cream, around 7 patients complained of mild discomfort during the procedure. Apart from these, no other complication was seen. A follow up period upto 6 months showed that the results are permanent and there were no other complications.

REVIEW OF THE LITERATURE AND DISCUSSIONS

In Ayurveda, *Hemadri*, the commentator of *Ashtanga Hridayam*,^[9] has described different types of ojas, among which the *Rasatmaka Ojas* can be considered as substances of complement system, antibodies; *Dhatutejorupi*- ojas can be considered as the tissue macrophages or all WBC's present in tissues; and *Shonita rupi ojas* as the WBC's in the blood. Thus the *Rasa-Rakta Dhatu*, *Rasatmaka Ojas*, *Shonitarupi Ojas*^[10] altogether which is continuously circulating in the intravascular compartment. This *Rasa Dhatu* is said to serve functions of nourishment (*Tarpayati*), growth (*Vardhayati*) and sustenance of tissues (*Dharayati*).^[11]

Among the cells in atypical blood sample, 93% are RBC's, 6% platelets, and 1% WBC's. the principle behind PRP treatment is to enrich the platelets through centrifugation, to reverse the RBC – to – platelets ratio to achieve a 94% concentration of platelets and 5% concentration of RBC's. the high level of growth factors and cytokines in PRP are thought to facilitate tissue rejuvenation and healing.

Platelets in this rich plasma are most often thought of for their haemostatic functions. However, they also contain a vast variety of over 800 proteins which, when secreted, act upon numerous targets including stem cells, fibroblasts, osteoblasts, endothelial and epithelial cells. Besides platelets and their secreted factors, there are other active components within PRP, importantly fibrinogen and leukocytes. Upon activation these growth factors lead to collagen induction and remodelling of acne scars. Another aspect consists of taking into consideration the half life of platelets (7-10 days) and to perform more frequent sessions to maintain long lasting stimulation by growth factors in dermis.

Functional similarities between PRP and *Rasa dhatu* can be considered as a type of *Rasayanam*, have a regenerative and healing role in skin rejuvenation (*Tvaka Rasayanam*).^[12]

In Ayurvedic prospective, the total therapy can be consider as follows.

1. *Siravyadha* – As nearly 50ml of blood (one *Anjali*) drawing from the patient – *Raktamokshana* benefits can be considered.^[13]
2. *Rasayanam* – *prasastha dhatu* replacing and doing *sandhana prakriya* with *Suchi* – Rejuvenating benefits can be considered.

CONCLUSION

Healthy, beautiful and attractive skin add charm to the personality. PRP has emerged as a new treatment modality. As PRP is made from one's self blood, the treatment is regarded as very safe, may effects in the patient's quality of life and self esteem. That's the PRP acts as a Rasayana Therapy is to impede the aging process by rejuvenating and reverse the skin miniaturization. It is easy to perform and shows effective results without any remarkable adverse effect in the treatment of acne vulgaris. At present the Ayurveda medicine is well accepted to re-orient itself to modern scientific parameters. So instead of just debating which healthcare system is better, a time has come to follow an integrative approach for the betterment of patients care.

REFRENCES

1. Rook's Textbook of Dermatology, 8th edition. Edited by DA Burns, SM Breathnach, NH Cox and CEM Griffiths. 2010 Blackwell Publishing Ltd. Cole GT.
2. Holland DB, Jeremy AH, Roberts SG et al. Inflammation in Acne Scarring: a comparision of responses in lesions from patients prone and not prone to scar. *Br J Dermatol*, 2004; 150: 72-81.
3. Agrawal S. Verma V, Gehlot S. Ayurvedic Perspectives on Physiology of Blood (Rasa-Rakta Dhatu) and it's Applied Aspects. *Int J Ayurveda & Med Sc*, 2016; 1(3): 70-76.
4. Murthy Shrikantha K.R., editor(1st Edition). Charaka Samihta of Agnivesha, voll. Sutrasthana; Dashapranayataniy Adhyaya: Chapter 29, verse 3. Varanasi: Chaukhambha Orientalia, 2004; 502.
5. Murthy Shrikantha K.R., editor(reprint Edition). Sushruta Samihta of Sushruta, Sutrasthana; Doshadhatumalakshayavidhi Adhyaya: Chapter 15, verse 3. Varanasi: Chaukhambha Orientalia, 2004; 97.
6. Robert E. Marx, DDS Platelet Rich Plasma. What is PRP and What is Not PRP ? *Implant Dentistry*, 2001; 10(4).
7. Steed DL. The Role of growth factors in wound healing. *Surg Clin North Am*, 1997; 77: 575-86.
8. Marx RE, Garg AK. Dental and Craniofacial Applications of Platelet Rich Plasma. Chicago: Quintessence Publishing, 2015.
9. Murthy Shrikantha K.R., editor(9th Edition). Ashtanga Hridayam of Vagbhata, Sutrasthana; Doshadivijaninya Adhayaya: Chapter 11, verse 37-38. Varanasi: Chaukhambha Krishandas Academy, 163.

10. Charak Samihta, Chikitsasthana, Grahani Dosha Vijaninya: Chapter 15, verse 36; p 21.
11. Charak Samihta, Sutrasthana, Vidhishonitiya adhyaya: Chapter 24, verse 4; p 351.
12. Sushrut Samihta, Sharirsthana, Dhamanivyakarana adhyaya: Chapter 9, verse 12; p 149.
13. Sushrut Samihta, Sutrasthana, Varnaprashna adhyaya: Chapter 21, verse 10; p 155.