



## Original Research Article

# Wound healing efficacy of novel ayurveda formulation- *Pentabark Kashaya*: In wistar rats using excision wound model- an in vivo study



Manjula B Madiwalar <sup>a,\*</sup>, Shindhe Pradeep S <sup>a</sup>, Rudramma Rachayya Hiremath <sup>b</sup>,  
Ramesh S Killedar <sup>a</sup>

<sup>a</sup> Dept of Shalya Tantra, KAHER'S Shri B M Kankanawadi Ayurveda Mahavidhyalaya Shahapur, Belagavi, Karnataka, India

<sup>b</sup> Department of Agad Tantra (Ayurvedic Forensic Medicine & Toxicology), KAHER'S Shri BMK Ayurved Mahavidyalaya, Belagavi, Karnataka, India

## ARTICLE INFO

## Article history:

Received 26 September 2020

Received in revised form

3 February 2022

Accepted 31 May 2022

Available online xxx

## Keywords:

*Pentabark kashaya*

Ayurveda

*Vrana*

Dermal toxicity

Wound healing

## ABSTRACT

**Background:** Wound healing plays a major concern in the field of surgery as it requires uneventful healing. Management aims towards prevention of infection and to accelerate healing. *Acharya Sushruta* has given more emphasis on *Vrana* (wound) and its *chikitsa* (treatment). Many antiseptic agents which prevent infection are widely used but have no role in accelerating the healing process and are cytotoxic, deleterious to wound healing. In this regard an innovative polyherbomineral formulation *Pentabark Kashaya* (PK) was formulated to assess acute dermal toxicity and woundhealing activity.

**Objective:** To explore the wound healing efficacy of novel Ayurveda Formulation i.e *Pentabark Kashaya* in Wistar rats using the excision wound model.

**Materials and method:** Acute dermal toxicity study was carried out on five female Wistar rats by following the OECD guideline 434 and signs of toxicity were assessed for the period of 14 days. Wound healing activity was assessed on the excision wound model. 18 male Wistar rats were procured for the study and divided into three groups (n = 6 in each group). The test group was treated with application of PK, standard group with Povidone iodine solution 5% and control group with distilled water. The parameters assessed were epithelialization period, wound contraction rate, wound closure day and swab test for microbial load for the period of 21 days. Statistical analysis was done by using one way ANOVA and Tukeys HSD to assess changes in between three groups at each time point.

**Results:** No signs of acute dermal toxicity were seen, which proved that PK is safe for application. Significant results were seen in the parameters of wound healing like period of epithelialization and wound closure day. Percentage of wound contraction rate was increased in test group when compared to other groups. Histopathology of skin showed marked changes in re-epithelialization, dermal fibroblast, dermal fibrocytes in test group when compared to control group.

**Conclusion:** PK is safe for application and it is effective in wound healing.

Clinical Trial Registration No.: Not applicable.

© 2022 The Authors. Published by Elsevier B.V. on behalf of Institute of Transdisciplinary Health Sciences and Technology and World Ayurveda Foundation. This is an open access article under the CC BY-NC-ND license (<http://creativecommons.org/licenses/by-nc-nd/4.0/>).

## 1. Introduction

Wounds are a significant cause of morbidity worldwide and studies proved that, for every million patients around 10,000 would die due to microbial infections [1]. A "wound" is defined as the disruption of normal anatomic structures and function [2].

Studies estimated that 5million patients get affected every year due to traumatic wounds [3]. *Acharya sushruta* has given utmost importance to *Vrana* (wound) and defines *vrana*(wound) as one which does the disruption of *shareeradhatu* (body tissues), leaves the *vranavastu* (scar) after *ropana* (healing) and remains till the end of life. He has described the classification of *vrana*, *sadya-asadyata* (prognosis) and its management in detail, which emphasizes the importance of wound care [4]. The major aim of the wound management is prevention of the infection and accelerating the healing process, which is achieved by use of topical antimicrobial dressing such as povidone iodine, soframycin and

\* Corresponding author.

E-mail: [manjulamadiwalar@gmail.com](mailto:manjulamadiwalar@gmail.com)

Peer review under responsibility of Transdisciplinary University, Bangalore.

silver containing products. Numerous antiseptic agents support to prevent contamination, infection of the wound but have no role in accelerating the natural healing process [5,6]. There is a necessity to develop such a preparation possessing Antibacterial, Anti-inflammatory and wound healing properties. In this regard an innovative polyherbomineral formulation i.e. *Pentabark Kashaya* was formulated by combining the drugs like *Panchavalkala kashaya*, *Shodhita Kasisa*, *Tuttha*, and *Sphatika*, so that an effective wound cleansing and healing agent can be brought into practice. *Panchavalkala Kashaya* is having the *Vrana Shodhana* and *Ropana* properties and being frequently used in every specialty of Ayurveda [7]. Recent researches proved that *Panchavalkala Kashaya* is effective in conditions like vaginitis, leucorrhoea, endometriosis, infected wounds and also possess anti-inflammatory, analgesic, antimicrobial and, anticancer activity [8]. The lacuna of using *Kashaya* is that it should be readily prepared and used immediately or else it loses its property (both in terms of efficacy and stability) [9]. It is a need of hour to enhance its efficacy, increase stability and make readily available compound for the usage so we have added *Shodhita Kasisa*, *Tuttha*, and *Sphatika* to the *Panchavalkala Kashaya* as these drugs possess property of *Krimighna*, *Vranashodhana* and *Vranaropana* [10,11].

Published research works in relation to *Panchavalkala* usage is available in the form of *kashaya*, powder and ointment in the management of wounds, but studies with additions of other herbal or mineral drugs to *panchavalkala* are not available [7]. Hence the present study was planned to prepare a novel formulation by combining *panchavalkala kashaya* with other mineral drugs followed with dermal toxicity and wound healing efficacy in excision wound model was undertaken.

## 2. Materials and methods

The present study was conducted in the Animal house of Shri B.M.K Ayurveda Mahavidyalaya, KAHER, Shahapur, Belagavi. This study was approved by the Animal Ethics Committee of the institution (IAEC letter number BMK/IAEC/Res No 06/2014 dated on 21st April 2014).

### 2.1. Source of raw drugs

*Vata* (*Ficus bengalensis* Linn), *Udumbara* (*Ficus racemosa* Linn), *Ashwatha* (*Ficus religiosa* Linn), *Parish* (*Thesposia populnea* Soland.), *Plaksha* (*Ficus infectoria* Roxb), *Kasisa* (Ferrous Sulphate ( $\text{FeSO}_4 \cdot 7\text{H}_2\text{O}$ )), *Tuttha* (Copper Sulphate ( $\text{CuSO}_4 \cdot 7\text{H}_2\text{O}$ )), and *Spatika* (Potash Alum ( $\text{K}_2\text{SO}_4 \cdot \text{Al}_2(\text{SO}_4)_3 \cdot 24\text{H}_2\text{O}$ )) were procured from the GMP certified KLE Ayurved Pharmacy, Belagavi. Authentication and quality control analysis of all raw drugs were done at AYUSH approved Drug testing laboratory, KAHER's B.M.K Ayurveda Mahavidyalaya, Belagavi.

### 2.2. Preparation of formulation

Ingredients required (Table 1) were taken in quantity as listed in the table. *Panchavalkala* (Stem barks of 5 plant) *Kashaya* (Decoction) 100 ml was prepared as per standard operative procedure [12]. Prepared *Kashaya* was taken in a steel vessel and it was mixed with *Shodhita Kasisa*, *Shodhita Tuttha* and *Shodhita Sphatika* as per the mentioned quantity. Preservatives, Sodium benzoate and Methyl paraben were added individually and stirred well till they were completely dissolved and was filtered and stored in a 100ml plastic bottle.

### 2.3. Animals

Experimental animals were procured from Animal House of KAHER's Shri J.N. Medical College, Belagavi. Animals were acclimatized to the laboratory conditions for seven days prior to the start of the study. They were housed in colony cages at an ambient temperature of  $22 \pm 3$  °C and relative humidity of 30%. Artificial lighting was arranged with the sequence of 12 hour light and dark, hygienic condition was maintained by replacing the floor bed every day. Animals were provided with free excess of standard pellet diet (Amrut feeds, VRK scientists choice Laboratory animals feed, Saiduurga feeds and foods, Bangalore) and fresh water *ad libitum*.

### 2.4. Acute dermal toxicity study [13]

Five female Wistar rats of 150–200 g were selected for the study. 10% of the total body surface area was shaved from the dorsal area of the trunk, 24 hours before the application of the test drug. The study includes two steps, i.e. Sighting and Limit test study to assess the dermal toxicity.

- Sighting study:** Test drug 2000 mg/kg body weight was applied to exposed skin of one rat through dropper and it was maintained in contact with the skin with a porous gauze dressing and non-irritating tape throughout 24 hour exposure period. After 24 hours, the skin was washed with luke warm water and wiped with gauze. Rat was observed for every hour up to 24 hours for any signs of toxicity.
- Limit test study:** The test substance 2000 mg/kg body weight was applied to exposed skin of next four female rats, after 24 hours the skin was washed with lukewarm water and wiped with gauze. Observations were done for every 24 hours up to 14 days for any signs of toxicity.

### 2.5. Excised Wound Healing Activity [14]

Healthy Male Wistar rats weighing between 150 and 200gm were divided into three groups containing six rats in each group. Group 1 was control group, Group 2 was the test group applied with PK and Group 3 was Standard group applied with 5% Povidone iodine solution.

**Creating excision wound:** The excised wounds were created in the animals as per reference of *Morton and Malone* Excision wound model. The dorsal fur of the rats was shaved with an electric clipper. Under light ether anesthesia, an impression of 2.5 cm was made on the dorsal inter scapular region using a circular seal. Full thickness skin of 2 mm depth and circular area 2.5cm x 2.5 cm was excised along the impression. The wound was traced on the polythene sheet and the animals were housed in individual cages.

Assessment of quantity of *Kashaya* required for application: Gauze piece weighed about 400 mg was taken, and with the help of dropper *Kashaya* was dropped on the gauze piece. 6 drops were sufficient for complete soakage of gauze.

**Wound Swab collection** – Aseptic precautions were followed by wearing the sterile gloves and samples of wound swab from the three groups were collected by identifying a small area (1 cm) of clean viable tissue and the swab was rotated for 5 s while applying enough pressure. Swab was carefully inserted into a sterile container and samples were immediately sent for microbial study [15,16].

**Method of Application:** The *Kashaya* was externally applied over raw surfaces of wound once daily after cleaning the previous application with the help of gauze piece. The study was conducted for the duration of 21 days. The assessment of wound closure was

**Table 1**  
Showing ingredients of 100 ml Pentabark Kashaya.

Sl.No	Name of Drug	Latin Name	Part used	Quantity
1	Vata	<i>Ficus bengalensis</i> Linn	Bark	10 gm
2	Udumbara	<i>Ficus racemosa</i> Linn	Bark	10 gm
3	Ashwatha	<i>Ficus religiosa</i> Linn	Bark	10 gm
4	Parisha	<i>Thesposia populnea</i> Soland.	Bark	10 gm
5	Plaksha	<i>Ficus infectoria</i> Roxb	Bark	10 gm
6	ShodhitaKasisa	Ferrous Sulphate (FeSO <sub>4</sub> 7H <sub>2</sub> O)		1 gm <sup>a</sup>
7	ShodhitaTutta	Copper Sulphate (CuSO <sub>4</sub> 7H <sub>2</sub> O)		25 mg <sup>a</sup>
8	ShodhitaSpatika	Potash Alum (K <sub>2</sub> SO <sub>4</sub> Al <sub>2</sub> SO <sub>4</sub> ) <sub>3</sub> 24H <sub>2</sub> O)		2.75 mg <sup>a</sup>
9	Sodium benzoate			10 mg
10	Methyl paraben			100 mg

<sup>a</sup> Note - Selection of quantity of Shodhita Tutta (0.012%), Kasisa (0.5–1%) and Spatika (1–10%) was made on the basis of text book inorganic pharmaceutical Chemistry by Bentley and Indian pharmacopoeia.

done by charting the raw wound surface area on every alternate day by transparent paper until complete wound healing.

These wound tracings were retraced on a millimeterscale graph paper, to determine the wound area. Calculation of Wound contraction (WC) was done as per following formula [17].

$$\text{i.e. Percentage of Wound Closure} = \frac{\text{Initial wound size} - \text{specific day wound size}}{\text{Initial Wound size}} \times 100$$

Epithelialization period was monitored by noting the number of days required for Escher to fall away, leaving no raw wound behind. Average Wound Closure Day was assessed by measurement and pictogram. The raw surface of the wound comes to the level of skin with scab on the upper surface was considered as wound closure day. The total microbial load was evaluated by taking woundswabs on the 1<sup>st</sup>, 3<sup>rd</sup>, and 12<sup>th</sup> day. Excisional biopsy of healed skin was sent for histopathological study to assess the quality wound healing.

Statistical analysis –The obtained results were stated in the form of mean ± SD. One way ANOVA and Tukeys HSD test were used to assess changes in between three groups at each time point. All p-value < 0.05 was considered to be statistically significant.

### 3. Results

#### 3.1. Acute dermal toxicity study

Sighting Study - No Mortality, no changes in behavior pattern, normal food and water intake, normal urine and stool frequency and no signs of toxicity were observed in experimental animals throughout the study tim period. No abnormal change in the body weight was observed and there was a normal increase in the body weight, i.e. 5-7 grams over 14 days duration.

Limit test Study – Four animals observed in limit test study did not exhibit any signs of toxicity and there was no mortality, rest of the parameters were normal throughout the study.

#### 3.2. Excised wound healing activity

1. Wound contraction rate - The percentage of wound contraction rate in the test group was significant on 4<sup>th</sup> day (36.03%), 8<sup>th</sup> day (83.87%), 12<sup>th</sup> day (91.60%), and 16<sup>th</sup> day (97.50%) when compared to the standard group on 4<sup>th</sup> day (30.20%), 8<sup>th</sup> day (73.78%), 12<sup>th</sup> day (86.70%), 16<sup>th</sup> day (92.93%) and control group

on 4<sup>th</sup> day (25.03%), 8<sup>th</sup> day (60.92%), 12<sup>th</sup> day (80.95%), 16<sup>th</sup> day (88.07%) (Table 2, Figs. 1 and 2).

The percentage of wound contraction rate in the test group was significant from 4<sup>th</sup> to 8<sup>th</sup> day (75.17%), 4<sup>th</sup> to 12<sup>th</sup> day (87.17%) and

4<sup>th</sup> to 16<sup>th</sup> day (96.33%) when compared to the standard group on 4<sup>th</sup> to 8<sup>th</sup> day (64.33%), 4<sup>th</sup> to 12<sup>th</sup> day (81.00%), 4<sup>th</sup> to 16<sup>th</sup> day (90.33%) and control group on 4<sup>th</sup> to 8<sup>th</sup> day (47.90%), 4<sup>th</sup> to 12<sup>th</sup> day (74.67%), 4<sup>th</sup> to 16<sup>th</sup> day (84.67%) (Table 2).

2. Epithelialization Time (in days)- Significant results were seen in test group i.e. p = 0.0006 and Mean ± SD (7.500 ± 1.049) when compared with control group (12.83 ± 1.329) and standard group (11.50 ± 1.049) (Table 3).

3. Wound Closure Day (WCD) - Significant results were seen in test group i.e. (p < 0.0001) and Mean ± SD (5.667 ± 0.8165) when compared with control (11.17 ± 0.9832) and standard group (9.000 ± 1.265) (Table 3). Total microbial load of wound: There was a reduction in total fungal count on 1<sup>st</sup> day, 3<sup>rd</sup> day and 12<sup>th</sup> day in the test group (14 cfu/ml, 14 cfu/ml, 07 cfu/ml) and standard group (16 cfu/ml, 12 cfu/ml, 05 cfu/ml) when compared to control group (13 cfu/ml, 24 cfu/ml, 27 cfu/ml). Reduction in the total bacterial count was seen on 1<sup>st</sup> day, 3<sup>rd</sup> day and 12<sup>th</sup> day in the test group (66 cfu/ml, 12 cfu/ml, 11 cfu/ml) and standard group (58 cfu/ml, 10 cfu/ml, 0 cfu/ml) when compared to control group (64 cfu/ml, 34 cfu/ml, 30 cfu/ml) (Table 4).

4. Histopathology of healed skin: The healed skin of animals in all the three groups was excised (1 × 1cm) and specimens were collected in formalin solution. Staining of specimens were done with hematoxylin and eosin reagents. 40× magnified images were obtained through microscope and readings were analyzed with the help of Microbiologist. Marked increase in the re-epithelialization, dermal fibroblast, dermal fibrocytes were seen in test group when compared to control group (Table 4).

### 4. Discussion

Wound healing is a natural process, which mainly depends on tissue regeneration [18]. Wound management always aims to enhance the wound healing process and reduce the risk factor like

**Table 2**  
Showing Comparison of three groups (Control, Standard and Test)with respect to mean area of wound (cm) and percentage of wound contraction at different time points.

Groups (n = 6 in each)	Summary	Area of wound(cm)				% of Wound contraction					
		4th	8th	12th	16th	4–8th	4–12th	4–16th	8–12th	8–16th	12–16th
Control	Mean	25.03	60.92	80.95	88.07	47.90	74.67	84.67	36.83	64.67	36.33
	±S.D	6.415	4.196	4.878	5.000	7.831	6.919	5.785	2.317	3.386	2.254
Test	Mean	36.03	83.87	91.60	97.50	75.17	87.17	96.33	56.00	83.50	59.00
	±S.D	5.003	1.832	2.156	0.5291	2.787	3.189	0.8165	2.280	3.987	2.280
Standard	Mean	30.20	73.78	86.70	92.93	64.33	81.00	90.33	47.33	72.50	45.33
	±S.D	3.379	3.974	3.065	2.938	7.474	4.648	3.983	2.803	3.584	2.803
F Value		14.26	48.01	17.15	16.61	24.61	12.84	20.93	11.83	9.146	5.005
P Value		0.0065*	<0.0001*	0.0020*	0.0042*	0.0009*	0.0025*	0.0011*	0.0021*	0.0155*	0.0382*

(Note: \*p < 0.05 C- control, S-standard, T-test).

**Table 3**  
Showing Comparison of three groups with respect to Epithelialization Time and Wound closure day.

Groups	Summary	Epithelialization time(days)	Wound closure day
Control	Mean ± SD	12.83 ± 1.329	11.17 ± 0.9832
Test	Mean ± SD	7.500 ± 1.049	5.667 ± 0.8165
Standard	Mean ± SD	11.50 ± 1.049	9.000 ± 1.265
F- value		45.22	36.68
P -value		0.0006	<0.0001

infection which directly impacts on the wound healing process. Researches are carried out in this direction with usage of various medicinal plants which has wound healing properties [19]. *Pentabark Kashaya* is a poly herbo-mineral new formulation, to ensure its safety acute dermal toxicity study was carried out prior to the wound healing effect on experimental animals.

4.1. Acute Dermal Toxicity study

There were no changes related to fur, skin, eyes, salivation, and central nervous system in all the animals of sighting and limit test study group till the end of study probable reason may be non-irritating nature of the drug which was absorbed through the dermal route but did not show any signs of toxicity. The overall effect of acute dermal toxicity study was drawn at the end of study based on all parameters. The drug did not show any dermal toxicity and is safe for external application.

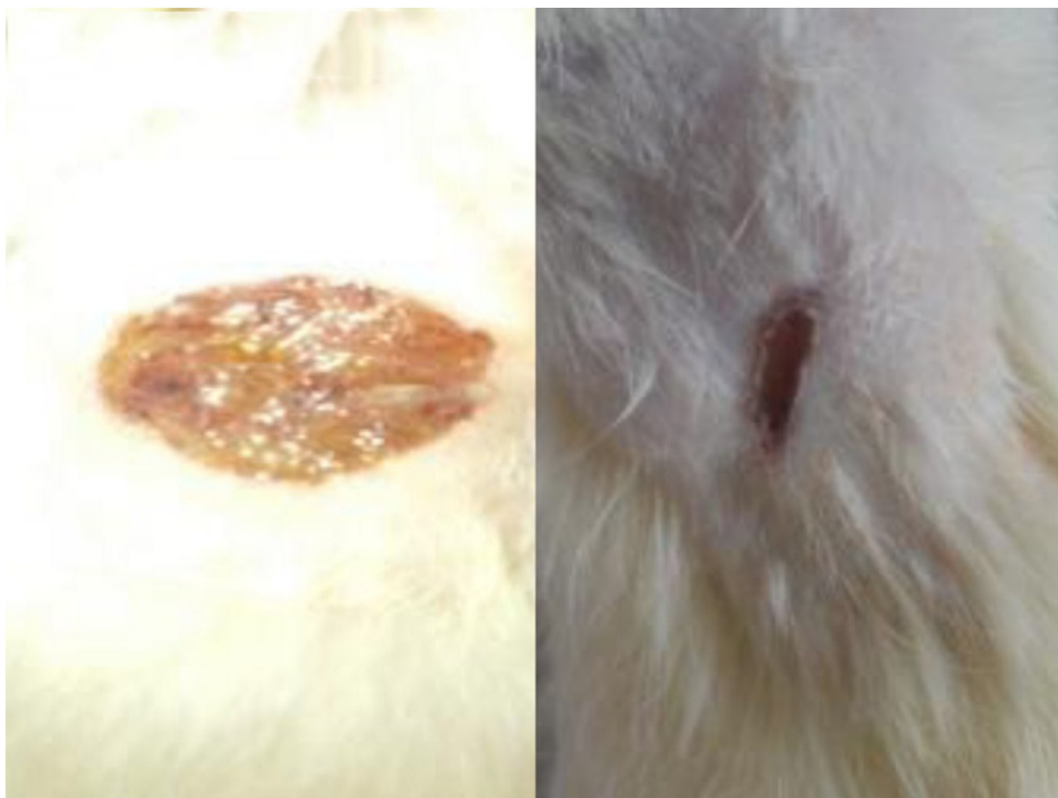**Table 4**  
Showing Total microbial load of wound and Histopathology of healed skin.

Total Microbial Load									
Sl.no	Group	Total fungal count			Total bacterial count				
		1 <sup>st</sup> day	3 <sup>rd</sup> day	12 <sup>th</sup> day	1 <sup>st</sup> day	3 <sup>rd</sup> day	12 <sup>th</sup> day		
1.	Control	13 cfu/ml	24 cfu/ml	27 cfu/ml	64 cfu/ml	34 cfu/ml	30 cfu/ml		
2.	Test	14 cfu/ml	14 cfu/ml	07 cfu/ml	66 cfu/ml	12 cfu/ml	11 cfu/ml		
3.	Standard	16 cfu/ml	12 cfu/ml	05 cfu/ml	58 cfu/ml	10 cfu/ml	08 cfu/ml		
Histopathology of Healed skin									
		Control group			Standard Group			Test Group	
1.	MICROSCOPY	-			+++			++++	
2.	Re-epithelialization	-			+			++	
3.	Dermal edema	++			-			-	
4.	Dermal Congestion	++			+			+	
5.	Dermal Inflammatory Infiltration	++			+			+	
6.	Neutrophocytic Infiltration	++			-			-	
7.	Lymphocytic Infiltration	+			+			+	
8.	Macrophages	+			-			-	
9.	Dermal Granulation Tissue	++			-			-	
10.	Dermal Fibroblasts	+			++			++	
11.	Dermal Fibrocytes	+			++			++++	
12.	Dermal Collagen/Fibrosis	+			+++			++++	
13.	Overall grade of healing	Poor			Good			Very Good	

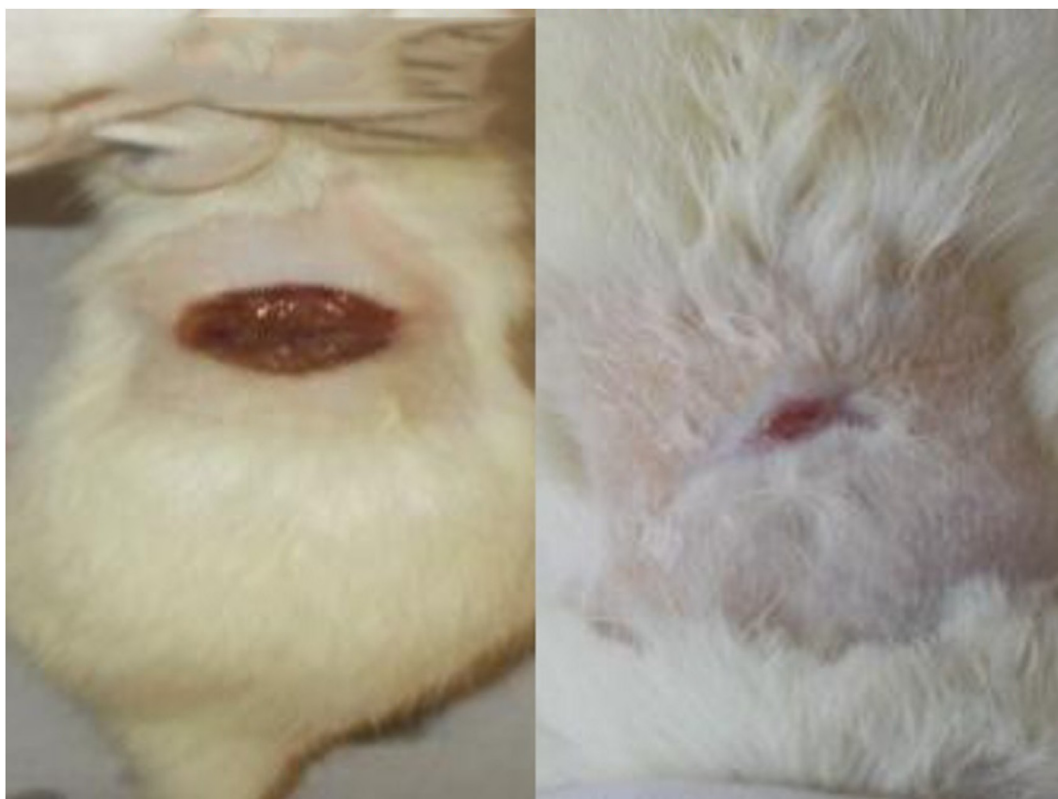4.2. Wound Healing study

Wound healing is a complex multi factorial process that results in the contraction and closure of the wound and restoration of a functional barrier [20]. An injured tissue always heals in three phases which consists of inflammation, proliferation, and remodelling [20]. There is an extensive loss of cells and tissues in an excised wound, and this makes the repair process more complicated [21].

- a) **Wound contraction:** Reduction of the wound size is an attempt to cover the raw surface area by the activity of myofibroblast which exerts centripetal force on wound margins thus increasing contractility. It is the process of mobilizing the healthy skin surrounding the wound to cover the denuded area [22]. In the present study test drug group showed a significant wound contraction rate (p < 0.0065) from the 4th day (Mean –36.03) itself compared to control (Mean - 25.03) and standard (Mean - 30.20) group. *Panchavalkala kashaya* is proved to possess antimicrobial, anti-inflammatory and wound healing properties. *Panchvalakala* contains Tannins, phytosterols and flavonoids which are proved to possess anti-inflammatory actions, antioxidant and blood purifying properties. Phytochemicals of *Panchavalkala* helps to prevent the prolongation of the initial phase by reducing infection there by promotes wound contraction, increases the collagen content and neoangiogenesis in the later phases (Fig. 1 and Fig. 2) [23]. *Shodhita Tutta* (CuSO<sub>4</sub>) is one of the ingredients; it clearly



**Fig. 1.** Wound of Control group 4<sup>th</sup> day (19/3/2015) and 16<sup>th</sup> day (31/3/2015).



**Fig. 2.** Wound of Standard group 4<sup>th</sup> day (19/3/2015) and 16<sup>th</sup> day (31/3/2015).

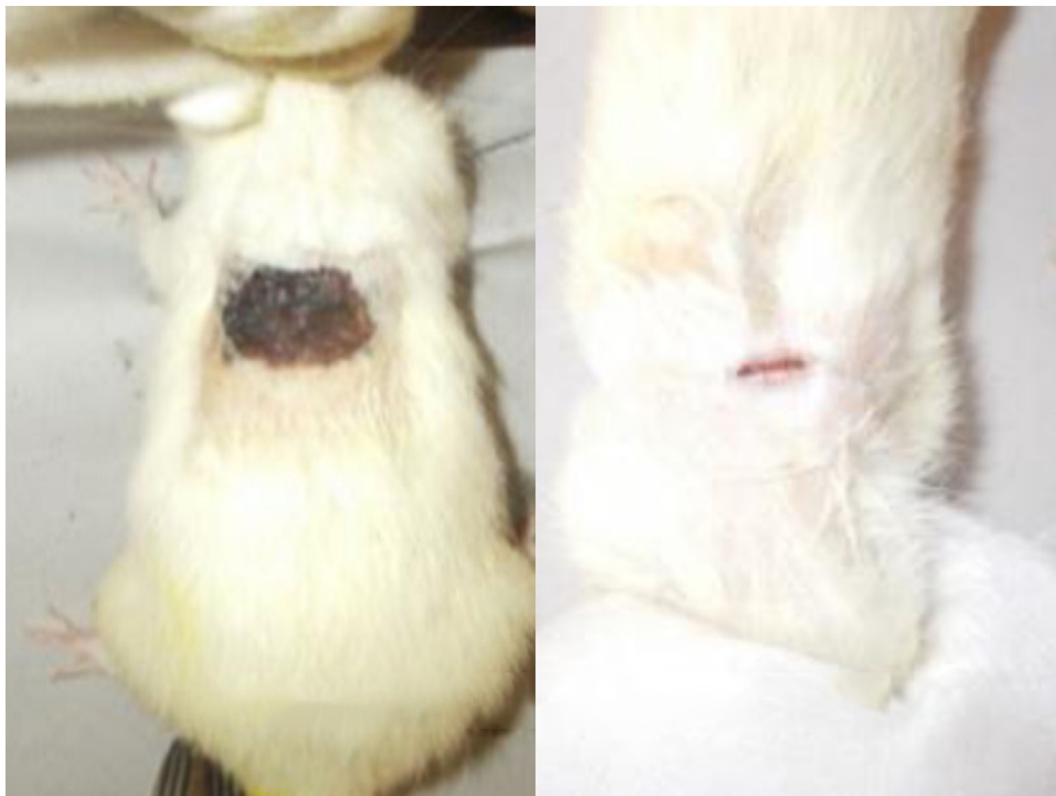

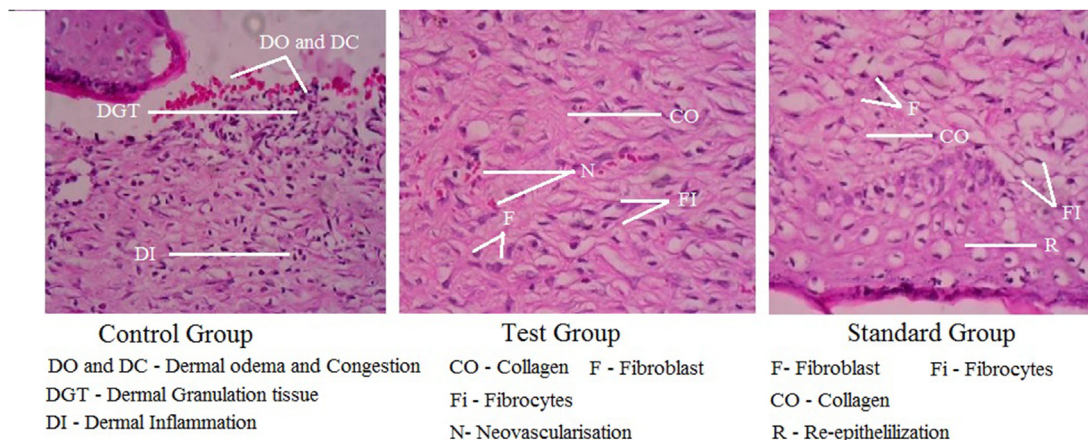
Fig. 3. Wound of Test group 4<sup>th</sup> day (19/3/2015) and 16<sup>th</sup> day (31/3/2015).

promotes angiogenic responses in wounds in both in vitro in vivo models [24]. Several copper-dependent enzymes, mainly amine oxidases, are known to be increased during wound healing. These copper-dependent enzymes are important in the remodeling and healing of the wounds [25]. *Sphatika* (Potash Alum) possess astringent and hemostatic properties and helps in the tissue contraction and reduces inflammation there by enhances wound healing [26]. *Shodhitakasisa* is known to possess *krimighna* (Antimicrobial) and *vranaghna* (wound healing) properties [27]. Recent researches showed similar wound contraction rate of polyherbal fractions of *Clinacanthus nutans* and *Elephanto pusscaber* when compared to PK [28]. A study conducted on polyherbal formulation showed similar results on excision wound healing model [17,29,30]. This emphasizes that, the test drug has started showing the wound healing effect from the initial day of the wound.

b) **Epithelialization time:** Test group (Mean - 7.5) showed significant reduction ( $p < 0.05$ ) in the epithelialization time compared to standard (Mean - 11.50) and control group (Mean - 12.83) (Fig. 1 and Fig. 2). Aqueous extract of *Ashwatha* (*Ficus religiosa*), *Vata* (*Ficus benghalensis*) *Udumbar* (*Ficus racemosa*), *Parisha* (*Thespesia populnea*) showed high rate of wound contraction, decrease in the period of epithelialization by collagen synthesis, high skin breaking strength in excision and incision wound models [29,31–33]. Previous researches on excision wound model using *Laghu panchamula* extract showed epithelialization time of 8.5 day but PK has showed at 7.5 days [34]. A study conducted on wound healing with roots of *Ficus racemosa* L. and other studies has showed similar results [29,35,36].

c) **Wound infection:** Infection of the wound is the major factor which hinders the normal healing process of wounds. Infection in the wound is due to the presence of necrotic tissue and disruption of protective barrier to microorganisms. Swab test performed on 1st day (14 cfu/ml), 3rd day (14 cfu/ml) and 12th day (7 cfu/ml) to see the microbial load of the wound showed progressive decrease in total bacterial load and total fungal count compared to control group (13 cfu/ml, 24 cfu/ml, 27 cfu/ml). This may be due to the antibacterial activity of the PK which forms the protective barrier on the wound [37]. PK showed progressive reduction in the microbial load with time, during the course of treatment, indicating the efficacy of the formulation in reducing the microbial load and thus controlling infection, facilitating wound healing [23]. Aqueous extract of *Panchavalkala* is known to possess antimicrobial activity thus reducing discharge, malodour and slough in the wound [23]. PK has shown antibacterial activity against selected gram positive and gram-negative bacteria like *Staphylococcus aureus* at the concentration of 50  $\mu\text{g/ml}$  in disc diffusion method and MIC 0.8  $\mu\text{g/ml}$ , *E. coli* 25  $\mu\text{g/ml}$  in disc diffusion method and MIC 3.12  $\mu\text{g/ml}$  and *Pseudomonas aeruginosa* 25  $\mu\text{g/ml}$  in disc diffusion method and MIC 50  $\mu\text{g/ml}$  [37]. *Tuttha* (Copper sulfate) has antibacterial activity against multi drug resistant bacteria [38].

d) **Wound closure day:** Test group (Mean - 5.667) showed a significant reduction ( $p < 0.0001$ ) in the wound closure day compared to standard (Mean - 9.0) and the control group (Mean - 11.17). Wound closure is a combination of wound contraction, mediated by myo fibroblasts, and re-epithelialization, which is caused by the penetration of the



**Fig. 4.** Histopathology of healed skin of Control, Standard and Test group (1/4/2015).

new epithelium into the granulation tissue [39]. Promotion of collagen synthesis by fibroblast, neoangiogenesis, increases amount of granulation tissue is due to presence of saponins, alkaloids, tannins in the *panchavalakala* which speeds up the regeneration process [23]. Recent studies on the *Jatyadi taila* application on the excision wound model showed wound healing on 9<sup>th</sup> day, but *PK* showed on the 8<sup>th</sup> day from post wounding [40] (see Fig. 3).

#### 4.3. Histopathology of skin

A marked increase in the re-epithelialization dermal fibroblast, dermal fibrocytes was seen in test group (Fig. 4) when compared to control group which shows that the drug has promoted collagen synthesis, neoangiogenesis and matrix modelling. The dermal collagen/fibrosis were increased in test group when compared to the standard and a control group which shows the minimal scar tissue formation.

Similar study conducted on wound healing activity showed the improvement of dermal collagen, neoangiogenesis and re epithelialization which was assessed by histopathology of skin [17,19]. *PK* contains *panchavalkala* which contains Tannins, Alkaloids, Saponins, Glycosides, Flavonoids, Phytosterols, which possesses antimicrobial, antioxidant, antiseptic, anti-inflammatory, wound purifying, healing, astringent properties [23]. *Tuttha*, *sphatika* and *kasisa* are known to possess astringent, angiogenic, antimicrobial, haemostatic and wound healing activities [24–27]. Thus *PK* helped in all stages of wound healing like inflammatory, epithelialization, angiogenesis, granulation tissue formation and collagen deposition.

#### 5. Conclusion

*Pentabark Kashaya* did not exhibit any signs of dermal toxicity on topical application. *PK* showed a significant improvement in the assessment parameters like wound contraction rate, epithelialization time, wound infection, wound closure day and histopathological changes. The study proves that *Pentabark Kashaya* is safe for application, effective in wound healing and readily available compound for the wound healing.

#### Funding source

KLE Ayurveda Pharmacy, Khasbag , Belagavi.

#### Declaration of competing interest

None.

#### Acknowledgements

Dr B. S. Prasad, Director, KLE Ayurved Pharmacy, Khasbag Belagavi for financial support to complete the research study.

#### Appendix A. Supplementary data

Supplementary data to this article can be found online at <https://doi.org/10.1016/j.jaim.2022.100602>.

#### References

- [1] Pruitt Jr BA, McManus AT, Kim SH, Goodwin CW. Burn wound infections: current status. *World J Surg* 1998;22:135–45.
- [2] Robson MC, Steed DL, Franz MG. Wound healing: biologic features and approaches to maximize healing trajectories. *Curr Probl Surg* 2001;38:72–140. [https://doi.org/10.1016/S0011-3840\(01\)70035-4](https://doi.org/10.1016/S0011-3840(01)70035-4) [PubMed] [CrossRef] [Google Scholar].
- [3] Kalaiselvan G, Dongre AR, Mahalakshmy T. Epidemiology of injury in rural Pondicherry, India. *J Inj Violence Res* 2011;3(2):62–7. <https://doi.org/10.5249/jivr.v3i2.74>.
- [4] Shastri Kaviraja Ambika Dutta, editor. *Sushruta samhita of acharya sushruta, chikitsa sthana, 1<sup>st</sup> chapter, verse 8. 1<sup>st</sup> ed. Reprint; Varanasi: Chowkhamba Sanskrit Sansthan; 2007. p. 397.*
- [5] Niedner R. Cytotoxicity and sensitization of povidone-iodine and other frequently Used anti-infective agents. *Dermatology* 1997;195(Suppl 2): 89–92.
- [6] Kramer SA. Effect of povidone-iodine on wound healing: a review. *J Vasc Nurs* 1999;17(1):17–23. PMID: 10362983.
- [7] Meena RK, Dudhamal T, Gupta SK, Mahanta V. Wound healing potential of *Panchavalkala* formulations in a postfistulectomy wound. *Ancient Sci Life* 2015;35(2):118–21. <https://doi.org/10.4103/0257-7941.171673>. PMID: 26865745.
- [8] Aphale S, Pandita S, Raina P, Mishra JN, Kaul-Ghanekar R. Phytochemical standardization of *panchavalkala*: an ayurvedic formulation and evaluation of its anticancer activity in cervical cancer cell lines. *Phcog Mag* 2018;14:554–6.
- [9] Narayana DBA. Stability studies of ayurvedic formulations. *Pharmatimes* 2005;37(6):45–50.
- [10] Killedar RS, Gupta S, Shinde P. Ayurveda management of Nicolau syndrome W.S.R to Kotha - a case report. *J Ayurveda Integr Med* 2021;12(1):165–8. <https://doi.org/10.1016/j.jaim.2020.07.004>.
- [11] Rupapara AV, Donga SB, Harisha CR, Shukla VJ. A preliminary physicochemical evaluation of Darvyadi Yoni Varti: a compound Ayurvedic formulation. *Ayu* 2014;35(4):467–70. <https://doi.org/10.4103/0974-8520.159048>. PMID: 26195915.
- [12] Sharangdhar samhita with “dipika Hindi commentary”, eited by brahmanand tripathi; reprint 2008. Choukamba Subharati Prakashana, Varanasi, Ch 17/71, p.146.

- [13] OECD guideline for testing of chemicals new draft guideline 434. May 2004. p. 14.
- [14] Morton Jjp MH. Evaluation of vulnary activity an open wound procedure in rats. Arch Int Pharmacodyn Ther 1972 Mar;196(1):117–26. PMID: 5059357.
- [15] Levine NS, Lindberg RB, Mason AD, Pruitt Jr BA. The quantitative swab culture and smear: a quick, simple method for determining the number of viable aerobic bacteria on open wounds. J Trauma 1976;16:89–94.
- [16] Gardner SE, Frantz RA, Saltzman CL, et al., Gardner SE, Frantz RA, Saltzman CL, Hillis SL, Park H, Scherubel M.. Diagnostisic validity of three swab techniques in identifying chronic wound infection. Wound Repair Regen 2006;14:548–57.
- [17] Talekar YP, Apte KG, Paygude SV, Tondare PR, Parab PB. Studies on wound healing potential of polyherbal formulation using in vitro and in vivo assays. J Ayurveda Integr Med 2017;8(2):73–81. <https://doi.org/10.1016/j.jaim.2016.11.007>.
- [18] Ankomah AD, Boakye YD, Agana TA, et al. Evaluation of Dermal Toxicity and Wound Healing Activity of *Cnestis ferruginea* Vahl ex DC. Adv Pharmacol Pharm Sci 2022;2022:5268613. <https://doi.org/10.1155/2022/5268613>.
- [19] Jahandideh M, Hajimehdipoor H, Mortazavi SA, Dehpour A, Hassanzadeh G. Evaluation of the Wound Healing Activity of a Traditional Compound Herbal Product Using Rat Excision Wound Model. Iran J Pharm Res 2017;16(Suppl): 153–63.
- [20] Sidhu GS, Mani H, Gaddipatti JP, Singh AK, Seth P, Banaudha KK, et al. Curcumin enhances wound healing in streptozotocin induced diabetic rats and genetically diabetic mice. Wound Repair Regen 1999 Sep-Oct;7(5):362–74. PMID: 10564565.
- [21] Cotran RS, Kumar V, Robbins SL. Inflammation and repair. In: Robbins pathologic basis of disease. 5<sup>th</sup> ed. Philadelphia: W.B. Saunders; 1994. p. 85–91.
- [22] Gabbaiani G, Harschel BJ, Ryan GB. Granulation tissue as a contractile organ. J Exp Med 1972 Apr 1;135(4):719–34.
- [23] Bhat KS, Vishwesh BN, Sahu M, Shukla VK. A clinical study on the efficacy of Panchavalkala cream in Vrana Shodhana w.s.r to its action on microbial load and wound infection. Ayu 2014;35(2):135–40. <https://doi.org/10.4103/0974-8520.146216>.
- [24] G1 Borkow, Gabbay J, Dardik R, Eidelman AI, Lavie Y, Grunfeld Y, et al. Molecular mechanisms of enhanced wound healing by copper oxide-impregnated dressings. Wound Repair Regen 2010 Mar-Apr;18(2):266–75. PMID: 20409151.
- [25] Alessandri G, Raju K, Gullino. Angiogenesis in vivo and selective mobilization of capillary endothelium in vitro by heparin-copper complex. Microcirc Endothelium Lymphatics 1984 Jun;1(3):329–46. PMID: 6546149.
- [26] Rafeian N, Abdolsamadi H, Moghadamnia A, et al., Rafeian N., Abdolsamadi H., Moghadamnia A. Jazayeri M, Seif-Rabiee M, Salmanzadeh M, Radi S. Efficacy of alum for treatment of recurrent aphthous stomatitis. Caspian J Intern Med 2016;7(3):201–5.
- [27] Sharma Shri Sadananda. Rasa tarangini by pandith kashinath shastri, vol. 564. New Delhi: Motilal Banarasidas; 2000. p. 772 [Chapter 21].
- [28] Aslam MS, Ahmad MS, Mamat AS, Ahmad MZ, Salam F. Antioxidant and wound healing activity of polyherbal fractions of *clinacanthus nutans* and *elephantopus scaber*. Evid Based Complement Alternat Med 2016;2016: 4685246. <https://doi.org/10.1155/2016/4685246>. Epub 2016 Jul 26. PMID: 27528881; PMCID: PMC4977412.
- [29] Murti K, Kumar U. Enhancement of wound healing with roots of *Ficus racemosa* L. in albino rats. Asian Pac J Trop Biomed 2012;2(4):276–80. [https://doi.org/10.1016/S2221-1691\(12\)60022-7](https://doi.org/10.1016/S2221-1691(12)60022-7).
- [30] Niknam S, Tofighi Z, Faramarzi MA, et al. Polyherbal combination for wound healing: *Matricaria chamomilla* L. and *Punica granatum* L. Daru 2021;29(1): 133–45. <https://doi.org/10.1007/s40199-021-00392-x>.
- [31] Chandrasekar SB, Bhanumathy M, Pawar AT, Somasundaram T. Phytopharmacology of *Ficus religiosa*. Pharm Rev 2010;4(8):195–9. <https://doi.org/10.4103/0973-7847.70918>.
- [32] Garg VK, Paliwal SK. Wound-healing activity of ethanolic and aqueous extracts of *Ficus benghalensis*. J Adv Pharm Technol Research 2011;2(2):110–4. <https://doi.org/10.4103/2231-4040.82957>.
- [33] Nagappa AN, Cheriyan B. Wound healing activity of the aqueous extract of *Thespesia populnea* fruit. Fitoterapia 2001 Jun;72(5):503–6. [https://doi.org/10.1016/S0367-326X\(01\)00275-1](https://doi.org/10.1016/S0367-326X(01)00275-1). PMID: 11429243.
- [34] Ghildiyal S, Gautam MK, Joshi VK, Goel RK. Wound healing and antimicrobial activity of two classical formulations of *Laghupanchamula* in rats. J Ayurveda Integr Med 2015;6(4):241–7. <https://doi.org/10.4103/0975-9476.157952>.
- [35] Elzayat EM, Auda SH, Alanazi FK, Al-Agamy MH. Evaluation of wound healing activity of henna, pomegranate and myrrh herbal ointment blend. Saudi Pharm J 2018;26(5):733–8. <https://doi.org/10.1016/j.jsps.2018.02.016>.
- [36] Demilew W, Adinev GM, Asrade S. Evaluation of the Wound Healing Activity of the Crude Extract of Leaves of *Acanthus polystachyus* Delile (Acanthaceae). Evid Based Complement Alternat Med 2018;2018:2047896. <https://doi.org/10.1155/2018/2047896>.
- [37] Madiwalar M, Pradeep SS, Hiremath RR, Killedar R. Evaluation of antibacterial activity of *Pentabark kashaya* against selected bacterial strains causing wound infection: in-vitro study. Int J Pharma Sci Res 2021;12(7):3687–92. [https://doi.org/10.13040/IJPSR.0975-8232.12\(7\).3687-92](https://doi.org/10.13040/IJPSR.0975-8232.12(7).3687-92).
- [38] Benhalima L, Amri S, Bensouilah M, Ouzrout R. Antibacterial effect of copper sulfate against multi-drug resistant nosocomial pathogens isolated from clinical samples. Pakistan J Med Sci 2019;35(5):1322–8. <https://doi.org/10.12669/pjms.35.5.336>.
- [39] Braiman-Wiksmann L, Solomonik I, Spira R, Tennenbaum T. Novel insights into wound healing sequence of events. Toxicol Pathol 2007;35:767–79.
- [40] Shailajana Sunita, Menon Sasikumar, Pednekaru Suhas, Singha Ashish. Wound healing efficacy of *Jatyadi Taila*: in vivo evaluation in rat using excision wound model. J Ethnopharmacol Oct 2011;138(1):99–104. <https://doi.org/10.1016/j.jep.2011.08.050>.